J Oral Maxillofac Surg
45:104–110, 1987

# Osteoradionecrosis:
## Clinical Experience and a Proposal for Classification

JOEL B. EPSTEIN, DMD, MSD,* FRANCES L. W. WONG, BSc, MD, FRCP(C),† AND P. STEVENSON-MOORE, BDS, MSD, MRCD(C)‡

Osteoradionecrosis is a severe complication of radiation therapy for cancer. Prevention of osteoradionecrosis is most important as the condition may be chronic, progressive and lead to pathologic fracture. The clinical experience at the Cancer Control Agency of British Columbia with 26 cases in approximately 1000 patients treated with radical radiation therapy to the head and neck region is presented and discussed. A clinical classification system is proposed to provide a guide for treatment selection, and to allow classification for research purposes.

The diagnosis of osteoradionecrosis is based primarily upon clinical signs and symptoms. The most common site of damage is the mandible. Ulceration or necrosis of the mucous membrane, with exposure of necrotic bone, is frequently seen. The lesion may be accompanied by neurologic symptoms of pain, dysesthesia or anesthesia. With mandibular involvement, such symptoms may be present in the distribution of the inferior alveolar nerve. Associated symptoms of fetor oris, dysgeusia, and food impaction in the area of the lesion also may be present. Exposure of rough, irregular bone may result in physical irritation of adjacent tissues. Progression of the condition may lead to pathologic fracture, intraoral and/or extraoral fistula formation, and local, spreading or systemic infection. Limitation of the mandibular opening, and difficulty in mastication, deglutition and speech may also accompany osteoradionecrosis.

Radiographic findings of an irregular radiolucent destruction of bone, with areas of irregular radiopacity indicative of sequestrum formation, may occur in osteoradionecrosis. Pathologic fracture may also be seen. Radiographic evidence of change is generally delayed, and the radiograph does not fully express the degree of involvement since such imaging requires a substantial alteration in mineral content and extensive involvement of the bone.[1,2] Bone scintigraphy may be of some assistance in diagnosing the degree of involvement, showing a lack of labeling in the area of the lesion.[1,2] The differential diagnosis of osteoradionecrosis must include recurrent or metastatic cancer.

Clinical evidence of osteoradionecrosis related to radiotherapy was first reported by Regaud in 1922.[3] The incidence of this condition has since been reported in a number of studies (Table 1). Articles published since 1970 suggest an incidence that ranges from 5–22%. Using the data reported in these studies from several institutions, a mean incidence of 10–15% can be derived.

The pathogenesis of osteoradionecrosis has been studied in an animal model in which high-dose, fractionated megavoltage radiotherapy was administered to the mandible of rhesus monkeys.[17] Blood vessels in the periodontum, periosteum, haversian bone and marrow were generally reduced in number and caliber. Similar histologic changes have been seen in human specimens, which correlate with the clinical findings.[18–20] The sequence of development of osteoradionecrosis is radiation, hypoxic-hypocellular-hypovascular tissue formation, and tissue breakdown.[19] The direct effects of radiation on the bone and the contiguous tissues is the initial factor that reduces vascularity and results in reduced vitality and impairment of reparative and regenerative capacity. Such tissues are

* Medical Dental Staff, Cancer Control Agency of British Columbia; Clinical Assistant Professor, University of British Columbia, Vancouver, British Columbia, Canada. Also Research Associate, Department of Oral Medicine, University of Washington, Seattle, Washington.

† Medical Dental Staff, Cancer Control Agency of B.C.; Clinical Assistant Professor, University of B.C., Vancouver, B.C., Canada.

‡ Medical Dental Staff, Cancer Control Agency of B.C.; Clinical Assistant Professor and Sessional Lecturer, University of B.C., Vancouver, B.C., Canada.

Address correspondence and reprint requests to Dr. Epstein: Division of Dentistry, Cancer Control Agency of B.C., 600 West 10th Avenue, Vancouver, B.C., V5Z 4E6, Canada.

0278-2391/87 $0.00 +.25

**Table 1. Reported Incidence of Osteoradionecrosis in Patients Radiated for Therapy of Cancer in the Oral Cavity and Oro/Nasopharynx**

| Author | Year | Total Patients | Cases | Site of Cancer |
|---|---|---|---|---|
| Watson and Scarborough[4] | 1938 | 1819 | 235 (12.9%)<br>(17.7%) | Oral<br>Exclude lip |
| Martin and Sugarbaker[5] | 1940 | 103 | 26 (25%) | Floor of mouth |
| MacComb[6] | 1962 | 251 | 93 (37.1%) | Oral |
| MacDougall et al.[7] | 1963 | 364 | 18 (5%) | Oral |
| Grant and Fletcher[8] | 1966 | 176 | 69 (37.5%) | Tonsil |
| Rahn and Drane[9] | 1967 | 120 | 53 (44.2%) | Oral |
| Rankow and Weissman[10] | 1971 | 176 | 12 (6.3%) | Oral |
| Wang[11] | 1972 | 262 | 15 (5.8%) | Tonsil |
| Cheng and Wang[12] | 1974 | 76 | 13 (17.1%) | Tonsil |
| Marciani and Plezia[13] | 1974 | 220 | 23 (10.5%) | Oral |
| Bedwinek et al.[14] | 1976 | 381 | 54 (14.2%) | Oral/pharynx |
| Murray et al.[15] | 1980 | 104 | 16 (15.4%) | Floor of mouth, Retromolar |
| Moorish et al.[16] | 1981 | 100 | 22 (22%)<br>(24% dentulous)<br>(14% edentulous) | Oral |

also less resistant to infection. Physical trauma and irritation, surgical manipulation, and infection are secondary factors that stress the healing capacity. Tissue necrosis occurs when the rate of healing is exceeded by the rate of tissue breakdown. Multiple factors are therefore involved in the pathogenesis of osteoradionecrosis in addition to radiotherapy.

Osteoradionecrosis may present as a lesion that heals spontaneously, as slowly progressive disease, or as an actively progressive symptomatic disease. The factors that are associated with differences in progression of the disease are not well known. To improve understanding of the disease process and its response to various treatment modalities, the results of treatment of patients with osteoradionecrosis at the Cancer Control Agency of B.C. were studied.

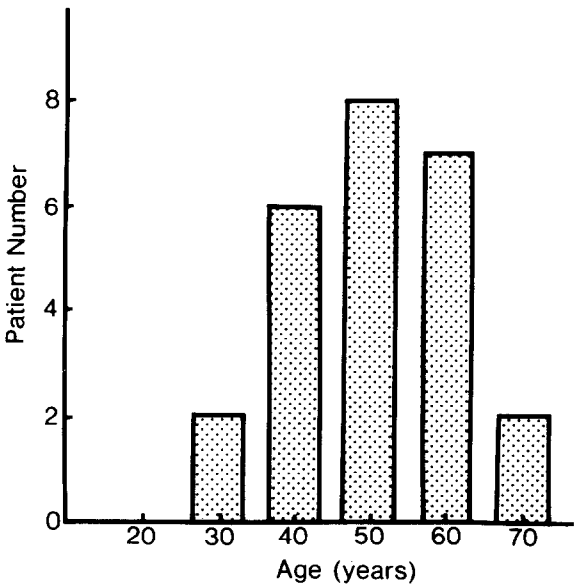


FIGURE 1. Age distribution of patients.

## Method

Medical charts of patients referred to the dental clinic of the A. Maxwell Evans Clinic of the Cancer Control Agency of British Columbia with a diagnosis of osteoradionecrosis were reviewed. Approximately 1000 patients with tumors of the head and neck region (excluding skin and orbital tumors) were treated with radical radiotherapy between September 1977 and April 1984. Twenty-seven patients with osteoradionecrosis were identified. However, one chart was not available and therefore was not included in this study.

## Results

The age distribution of the patients is shown in Figure 1. The majority of the patients were 50 years or older. The male to female ratio was 1.6:1. The site of the primary tumors treated are listed in Table 2. The primary tumor was staged using the W.H.O. TNM staging system (Table 3). Two patients were not staged as one had a recurrent adenoidcystic carcinoma of the upper alveolus and the other had a benign mixed adenoma of the soft palate.

All patients received radiotherapy for treatment of the primary tumor. Twenty received external megavoltage, beam-directed treatments only. Four were treated with interstitial gold seeds or radioactive needle implants. Two were treated with combined interstitial and external beam therapy. How-

**Table 2. Site of Primary Tumor of Patients with Osteoradionecrosis**

| | Site | Number |
|---|---|---|
| Antrum | | 1 |
| Oropharynx | Tonsil | 3 |
| | Palate | 1 |
| | Retromolar trigone | 1 |
| Tongue | | 8 |
| Oral cavity | Floor of mouth | 10 |
| | Alveolus | 1 |
| Nasopharynx | | 1 |

**Table 3. Stage of Primary Tumors**

| | | T 1 | T 2 | T 3 | T 4 |
|---|---|---|---|---|---|
| Nodes | N 0 | 3 | 7 | 2 | 1 |
| | N 1 | 3 | 7 | 1 | — |
| | N 2 | — | — | — | — |
| | N 3 | — | — | — | 1 |
| | Total | 6 | 14 | 3 | 1 |

ever, one of these patients developed osteoradionecrosis prior to the addition of external field radiation. The number of fields used for those who received external beam radiation only are listed in Table 4.

The radiation dose received by the patients varied. The absorbed radiation dose was expressed in centigrays (cGy), the standard international unit (1 cGy = 1 rad). The time, dose and fractionation factors of radiotherapy are calculated and expressed as TDF. For external beam therapy, the dose varied from TDF 105 (6250 cGy in 30 fractions over 43 days) to TDF 127 (5500 cGy in 15 fractions over 15 days). These were the prescribed tumor doses, not the actual calculated mandibular doses. However, the mandible was usually within the high dose volume. Most of the patients received the standard tumor dose of 6000 cGy in 25 fractions over 35 days (TDF 109). Radiation doses provided by interstitial implants are shown in Table 5.

The clinical status of the patients with osteoradionecrosis is shown in Table 6. In patients with resolution of osteoradionecrosis, mucosal and bony integrity were maintained or restored, and the patient was free of pain. Resolution occurred in 15% of patients. Chronic non-progressive necrosis was present in 42% of patients. In these patients, the exposure of bone remained static, and no progression of symptoms occurred. Neurologic symptoms were stable, and pain, when present, was well controlled. Fifty-seven per cent of patients had symptoms controlled or resolved. Twenty-three per cent of patients developed a pathologic fracture, and 19% continued to show signs and symptoms of active, progressive osteoradionecrosis.

Possible factors relating to the development of osteoradionecrosis following radiotherapy were analyzed. Dental manipulation or denture irritation were related to the development of osteoradionecrosis in 11 patients (Table 7). No predisposing factors could be identified in 12 patients. The necrotic sites were cultured with aerobic technique; however, no pathogens were identified. The interval between the completion of radiotherapy and diagnosis of osteoradionecrosis averaged 4.5 months in the dental surgical group, but could be as long as 13 years in the spontaneous group. Fifty per cent of the patients who did not have identifiable predisposing factors developed osteoradionecrosis within six months of radiotherapy.

Treatment of osteoradionecrosis varied according to the severity of the condition and the attending physician. Patients were advised to avoid potential irritants, including alcohol and tobacco. Good oral hygiene and cleanliness of the lesion were emphasized. Patients were instructed in irrigation of the lesion with the aid of a syringe. Additional treatment included the use of an antibiotic or antiseptic. Patients initially were provided with tetracycline, 250 to 500 mg qid. If use of the antibiotic resulted in gastrointestinal upset, the antibiotic was changed to penicillin or rovamycin (spiramycin). Chlorhexidine gluconate (0.2% aqueous solution) was used twice daily on a two week on, two week off basis as a topical antiseptic rinse. Discomfort and pain were

**Table 4. Fields Used in External Beam Radiotherapy**

| Plan of Therapy | No. of Fields |
|---|---|
| Dominant anterior | 1 |
| Wedge pair | 6 |
| Parallel pair | 7 |
| 3 fields | 4 |
| 7 fields | 1 |
| 3 fields + electron | 1 |

**Table 5. Radiation Dose to Primary Lesions**

External beam:
TDF 105–127
10/20 patients: TDF 109
Interstitial therapy:
Needle implant 7000 cGy/7 days
6715 cGy/115 hr
6500 cGy/5 days
Gold seeds 8770 cGy
Interstitial and external beam:
TDF 120 + Gold seeds 3500 cGy
TDF 95 + 6500 cGy/7 days

managed with analgesics as needed. Rough, irregular, exposed bone was smoothed and sequestra gently removed when they were accessible. Hyperbaric oxygen therapy was offered only to patients with actively, progressive symptomatic osteoradionecrosis. Three patients received hyperbaric oxygen treatment for five separate episodes of osteoradionecrosis.

The results of treatment of the 32 episodes of osteoradionecrosis in the 26 patients are shown in Table 8. During the study period, the approach to management of osteoradionecrosis at the Cancer Control Agency was essentially conservative and nonsurgical. Twenty-six episodes were managed in this manner. Complete healing and resolution of symptoms was seen in eight instances. Five episodes were reported to be improving. In 12 cases, stable, asymptomatic, but persistent areas of osteoradionecrosis remained. One case had progression of the condition. Hyperbaric oxygen therapy, in addition to the other conservative treatments, resulted in resolution in two episodes; a stable, but persistent condition in two; and, in spite of the treatments, a worsening condition in one case. One episode of necrosis was managed by surgical excision or closure with resolution of the lesion. No patients were managed with combined hyperbaric oxygen and surgical therapy. None of the patients who developed a pathological fracture were surgically reconstructed. Regardless of the treatments used, osteoradionecrosis persisted in six of nine patients who were treated with external beam therapy of a dose greater than TDF 109.

## Discussion

Osteoradionecrosis is a severe complication of cancer treatment and can result in prolonged suffering of patients. The incidence of osteoradionecrosis in this study was 2.6% (26 of 1000 patients treated). This is a lower incidence rate than reported by others (Table 1). The incidence of osteoradionecrosis from the Cancer Control Agency has been reported previously to be 5% during the period of 1940 to 1959.[7] The possible under-reporting is a limitation of all retrospective studies of the condition. However, the lower incidence reported in this study may be due to better preradiation oral assessment and dental care, radiation treatment planning, and proper care following radiation therapy.

**Table 6. Clinical Status of Patients with Osteoradionecrosis**

| | Resolved | Chronic, Persistent | Active, Progressive | Pathologic Fracture |
|---|---|---|---|---|
| Number of patients | 4/26 (15%) | 11/26 (42%) | 5/26 (19%) | 6/26 (23%) |

**Table 7. Possible Predisposing Factors in Osteonecrosis (Excluding Radiation)**

| Factor | Patients (*n*) |
|---|---|
| Dental | |
| Extraction | |
| Pre-radiation | 2 |
| Post-radiation | 7 |
| Denture irritation | 2 |
| | 11 |
| Surgery | |
| Caldwell-Luc | 1 |
| Radical neck dissection | 2 |
| | 3 |
| Idiopathic (spontaneous) | 12 |

Prior to radiation therapy all patients received a complete oral and dental examination, and the required dental care was provided. This included selective extraction of nonsalvagable teeth, management of denture irritation, dental prophylaxis, oral hygiene instruction, and a caries prevention program using fluoride gel applications in mouth guard fluoride carriers. Following radiotherapy, patients were seen for assessment of the results of therapy and for assessment of their oral and dental condition. If any surgical therapy was unavoidable, it was conducted by specialist consultants of the Cancer Control Agency, with appropriate antibiotic coverage, atraumatic surgery, and primary closure of the surgical site without tension in the tissues.

The majority of patients who developed osteoradionecrosis were males aged 50 years or older. This was in keeping with the population profile of patients with head and neck cancer. All patients received radiation therapy in the treatment of the primary tumor with the external beam directed technique and/or radioactive implant. The external beam radiation dose to the tumor site varied from TDF 105 (6250 cGy in 30 fractions) to TDF 127 (5500 cGy in 15 fractions), with most patients receiving TDF of 109 (6000 cGy in 25 fractions in five weeks). The mandible would be within the high dose volume. The dose to bone with the use of interstitial implants was more difficult to estimate due to the variable distance of the affected bone from the radiation source and the different absorption coefficient between soft tissue and bone. No effort was made to deflect oral tissues containing interstitial implants from the mandible.

Murray and others found that the tumor site, ra-

**Table 8. Response to Treatment of Osteoradionecrosis**

| Treatment | Episodes | Treatment result | | | |
|---|---|---|---|---|---|
| | | Resolved | Improved | Stable | Worse |
| Conservative | 26 | 8 | 5 | 12 | 1 |
| Conservative and hyperbaric $O_2$ | 6 | 2 | — | 2 | 2 |
| Surgical repair | 1 | 1 | — | — | — |

diation treatment dose and volume, and dental status of patients related to the development of necrosis.[15,21-24] In this study radiation dose to the bone was also identified as an important factor. Osteoradionecrosis was resistant to nonsurgical management in patients who received high doses (greater than TDF 109). The importance of the preradiation dental status could not be determined as all patients received preradiation evaluation and dental treatment and a caries prevention program. In agreement with others, the location and stage of tumor was not shown to be related to the development of osteoradionecrosis.

No specific factors were associated with the onset of necrosis in 46% of patients in this study. Others have reported the importance of dental extraction, jaw surgery for disease, and denture trauma as stimuli that may precipitate necrosis.[15,21,23] The common etiologic factors reported in this study were very similar to the incidence of these factors reported by Beumer and others.[23] Improvement in the prevention of osteoradionecrosis with appropriate dental assessment, pre-radiation dental treatment and caries prevention programs may account for the high number of idiopathic or "spontaneous" cases reported in this study and by others.[21,23]

The mean time of onset of osteoradionecrosis following radiation therapy was less than six months, with a range of two days to 13 years. The risk of developing necrosis was greatest in the first six months following treatment. Others have shown the greatest risk during the first 12 months and diminishing gradually after one year.[22,23,25] However, the risk of developing osteoradionecrosis persists for years after radiation therapy since the reduction in healing capacity may be permanent.[26-29]

Treatment of osteoradionecrosis in this study was primarily nonsurgical or "conservative." Fifty-seven per cent of the cases resolved or were stable and non-progressive (15% complete resolution and 42% stable). However, 23% developed pathologic fractures during the study period and 19% of cases remained symptomatic and progressive. Hyperbaric oxygen therapy was used as an adjunct to conservative therapy in only three patients, each of whom had two episodes of osteoradionecrosis. Hyperbaric oxygen was used when progression was seen clinically in spite of conservative therapy. One third of the episodes resolved, one-third remained stable, and one third remained active (Table 8). This suggested that hyperbaric oxygen alone does not necessarily lead to resolution of osteoradionecrosis lesions. This could be explained on the basis of the variability of the degree of radiation injury and variability in the healing capacity between patients, as well as the fact that necrotic bone cannot be reversed by hyperbaric oxygen alone.

Hyperbaric oxygen has been reported to enhance wound healing by promoting vascularization.[19,22,23,30-33] Farmer et al. studied the use of hyperbaric oxygen and found resolution in 54% and improvement in 23% of the patients. Mansfield and others used hyperbaric oxygen therapy as an adjunct to conservative measures and reported favorable responses in 92% of cases. Marx has reported successful resolution in all of 58 cases of osteoradionecrosis using hyperbaric oxygen in combination with surgery. Beumer et al.[23] noted that bony exposure within the attached gingival tissues did well with conservative measures; however, lesions initially extending beyond the attached tissues progressed to require surgical resection. Hyperbaric oxygen was of less benefit in patients with limited compliance and poor control of local factors. Hyperbaric oxygen was found particularly helpful in treatment of large areas of necrosis when used in combination with surgical sequestrectomy. Excellent results could be obtained because surgical therapy provided wound debridement and removal of large areas of necrotic bone, and the hyperbaric therapy improved the healing capacity of the involved tissues.

Due to the heterogeneous presentation of osteoradionecrosis and its response to treatment, a system of classification based upon clinical and radiographic findings would facilitate treatment decisions and classification for research purposes. The staging system used at Wilford Hall[30] was based upon the response of selected patients to treatment with hyperbaric oxygen and aggressive surgical debridement. A clinical staging classification is proposed to reflect the progress of the condition (Table 9). Stage I represents healed, resolved osteoradionecrosis. Pathologic fracture may have occurred (Stage Ib), but the patient will have been reconstructed to provide continuity of the jaw. Stage II includes patients with chronic (>three months), persistent osteoradionecrosis. The lesion is not tender, remains stable in size, and neurologic symptoms of paresthesia and anesthesia, if present, are not progressive. The patient is either pain free

**Table 9. Clinical Classification and Treatment of Osteoradionecrosis**

| Stage | Description | Symptoms | Treatment |
|---|---|---|---|
| I | Resolved, healed | None | Follow-up, prevention of recurrence |
| Ia | No pathologic fracture | | |
| Ib | Pathologic fracture | | Reconstructed |
| II | Chronic, persistent non-progressive | None, or controlled | Local wound care<br>Antiseptics/antibiotics, analgesics, hyperbaric oxygen (if indicated) [Wilford Hall Staging][30] |
| IIa | No pathologic fracture | | |
| IIb | Pathologic fracture | Jaw dysfunction | |
| III | Active, progressive | Progressive | Local wound care<br>Antiseptics/antibiotics, analgesic, hyperbaric oxygen [Wilford Hall Staging][30] |
| IIIa | No pathologic fracture | | |
| IIIb | Pathologic fracture | Jaw dysfunction | |

or the discomfort is well controlled. Patients may have a pathologic fracture (Stage IIb) and compromised jaw function; however the symptoms are stable. In stage III, the patient with progressive, active osteoradionecrosis manifest signs and symptoms of continuing disease. Resolution of the necrotic lesion and reversion to Stage I disease is the goal of treatment.

Selection of treatment of osteoradionecrosis must depend upon the presentation of the necrotic lesion, the response to conservative nonsurgical therapy, the general health of the patient, the prognosis for successful management of the cancer, and the wishes of the patient. Continuing management must include meticulous hygiene and avoidance of irritants. Although hyperbaric oxygen may be used for Stage II disease to maximize tissue viability; chronic, nonprogressive osteoradionecrosis may be acceptable, particularly if function is not compromised. Progressive lesions (Stage III) that do not respond to conservative management should be treated aggressively with hyperbaric oxygen and surgery. The treatment received by these patients can be described using the Wilford Hall Staging.[30]

## Conclusions

Osteoradionecrosis is a complication that may follow radiation therapy for cancer. It may be long standing and difficult to manage. Prevention is paramount. Meticulous oral and dental care is vital prior to and following radiation therapy. The dose and fractionation of the radiotherapy is important, as patients who receive high doses (TDF > 109) are more resistant to conservative management of the osteoradionecrosis.

The treatment of osteoradionecrosis remains variable. Conservative care is basic in management. The function of local measures and antimicrobial agents is to decrease the demands on the compromised tissue. The effect of hyperbaric oxygen is to enhance the tissue healing potential. Classification of the condition when initially diagnosed is necessary in order to compare the results of treatment at different centers.

## References


1. Epstein JB, Hatcher DC, Graham M: Bone scintigraphy of fibro-osseous lesions of the jaw. Oral Surg 51:346, 1981
2. Bergstedt HS: Bone scintigraphy of facial skeleton with 99Tcm-Diphosphonate. Acta Radiol (Diagn) 16:337, 1975
3. Regaud C: Sur la necrose des os attients par un processus cancereux et traiters par les radiations. Compt Rend Soc de Biol 87:427, 1922
4. Watson WL, Scarborough JE: Osteoradionecrosis in intraoral cancer. Am J Roentgen 40:524, 1938
5. Martin HE, Sugarbaker EL: Cancer of the floor of the mouth. Surg Gynecol Obstet 71:347, 1940
6. MacComb W: Necrosis in the treatment of intraoral cancer by radiation. Am J Roentgen 87:431, 1962
7. MacDougall JA, Evans AM, Lindsay RK: Osteoradionecrosis of the mandible and its treatment. Am J Surg 106:816, 1963
8. Grant B, Fletcher G: Analysis of complications following megavoltage therapy for squamous cell carcinoma of the tonsillar area. Am J Roentgen 96:28, 1966
9. Rahn AO, Drane JB: Dental aspects of the problems, care and treatment of the irradiated oral cancer patient. JADA 74:957, 1967
10. Rankow RM, Weissman B: Osteoradionecrosis of the mandible. Ann Otolaryngol 80:603, 1971
11. Wang CC: Management and prognosis of squamous cell carcinoma of the tonsillar region. Radiology 104:667, 1972
12. Cheng VST, Wang CC: Osteoradionecrosis of the mandible resulting from external megavoltage radiation therapy. Radiology 112:685, 1974
13. Marciani RD, Plezia RA: Osteoradionecrosis of the mandible. J Oral Surg 32:435, 1974
14. Bedwinek JM, Shukovsky LJ, Fletcher GH, et al: Osteoradionecrosis in patients treated with definitive radiotherapy for squamous cell carcinomas of the oral cavity and naso- and oropharynx. Radiology 119:665, 1976
15. Murray CG, Daly TE, Zimmerman SO: The relationship be-

tween dental disease and radiation necrosis of the mandible. Oral Surg 49:99, 1980
16. Moorish RB, Chan E, Silverman S Jr, et al: Osteoradionecrosis in patients irradiated for head and neck carcinoma. Cancer 47:1980, 1981
17. Roher MD, Kim Y, Fayos JV: The effect of cobalt-60 irradiation on monkey mandibles. Oral Surg 48:424, 1979
18. Pappas GC: Bone changes in osteoradionecrosis. Oral Surg 27:622, 1969
19. Marx RE: Osteoradionecrosis: a new concept of its pathophysiology. J Oral Maxillofac Surg 41:283, 1983
20. Beumer J, Curtis TA: Radiation therapy of head and neck tumors, *in* Beumer J, Curtis TA, Firtell DW (eds): Maxillofacial Rehabilitation. St. Louis, CV Mosby, 1979, pp 43–89
21. Murray CG, Herson J, Daly TE, et al: Radiation necrosis of the mandible: a 10 year study, part I. Factors influencing the onset of necrosis. Int J Radiat Oncol Biol Phys 6:543, 1980
22. Murray CG, Herson J, Daly TE, et al: Radiation necrosis of the mandible: a 10 year study, part II. Dental factors, onset, duration and management of necrosis. Int J Radiat Oncol Biol Phys 6:549, 1980
23. Beumer J, Harrison R, Sanders B, et al: Osteoradionecrosis: predisposing factors and outcomes of therapy. Head Neck Surg 6:819, 1984
24. Beumer J, Harrison R, Sanders B, et al: Preradiation dental extractions and the incidence of bone necrosis. Head Neck Surg 5:514, 1983
25. Starcke EN, Shannon IL: How critical is the interval between extractions and irradiation in patients with head and neck malignancy. Oral Surg 43:333, 1977
26. Stein M, Brady LW, Raventos A: The effects of radiation on extraction wound healing in the rat. Cancer 10:1167, 1957
27. Shearer HT: Effect of cobalt-60 radiation on extraction healing in the mandible of dogs. Oral Surg 25:115, 1967
28. Daly TE, Drane JB: Management of dental problems in irradiated patients. The University of Texas at Houston, MD Anderson Hospital and Tumor Institute and Dental Branch, 1972, pp 1–43.
29. Guttenberg SA: Osteoradionecrosis of the jaws. Am J Surg 127:326, 1974
30. Marx RE: A new concept in the treatment of osteoradionecrosis. J Oral Maxillofac Surg 41:351, 1983
31. Farmer JC, Shelton DL, Angelillo JD, et al: Treatment of radiation induced tissue injury by hyperbaric oxygen. Ann Otolaryngol 87:707, 1978
32. Mansfield MJ, Sanders DW, Heimbach RD, et al: Hyperbaric oxygen as an adjunct in the treatment of osteoradionecrosis of the mandible. J Oral Surg 39:585, 1981
33. Mainous EG, Boyne PJ: Hyperbaric oxygen in total rehabilitation of patients with mandibular osteoradionecrosis. Int J Oral Surg 3:297, 1974